

Late postoperative slippage of the cerebral aneurysm clip. A systematic review and meta-analysis

Tomasz Szmuda  , Paweł Słoniewski 

Department of Neurosurgery, Medical University of Gdańsk, Poland

Abstract

Background: A late clip slippage from the previously properly secured cerebral aneurysm is rarely observed. To date these complications have not pooled and evaluated using systematic review methodology. The objective was to report factors attributed to the late slippage of the aneurysm clip in the postoperative period. **Materials and methods:** All causes of postoperative clip slippage were systematically reviewed and analysed according to PRISMA Individual Patient Data protocol. Medline (PubMed), Embase, Cochrane, ISI Web of Knowledge and Google Scholar were searched for all relevant cases. **Results:** Systematic review of the literature yielded 105 original cases proving slipped clip in the postoperative period. The slipped clip caused bleeding in 53.8% of patients. The putative cause of clip slippage was provided in only 34.7% of the published cases. If a single clip was used, then complete clip slippage was noted more often ($p=0.04$). Multiple clipping and clip-wrapping techniques were postulated as ways to prevent postoperative clip slippage. **Conclusions:** The reason for late slippage of the aneurysm clip remains unexplained by most authors. Based on systematic reviewing, the use of tandem of clips prevents their late migration off the aneurysm. Clipping with wrapping or use of a single clip reinforced by any wrapping material seems a more durable solution.

Keywords: systematic review • intracranial aneurysm • clip slippage • neurosurgical clipping

Citation

Szmuda T, Słoniewski P. Late postoperative slippage of the cerebral aneurysm clip. A systematic review and meta-analysis. *Eur J Transl Clin Med.* 2019;2(1):56-69.
DOI: 10.31373/ejtc/103442

Corresponding author:

Tomasz Szmuda, Department of Neurosurgery, Medical University of Gdańsk, Poland
e-mail: tszmuda@gumed.edu.pl

No external funds.

Available online: www.ejtc.gumed.edu.pl

Copyright © Medical University of Gdańsk

This is Open Access article distributed under the terms of the Creative Commons Attribution-ShareAlike 4.0 International.



Background

Postoperative clip slippage is a rarely observed complication. Authors attributed this complication to the application of a short clip, some alloy features or clip closing pressure [1, 2]. Repetitive opening of the clip further reduces its closing forces [3-5]. Another factor is the so-called scissoring effect [6-9]. Various authors demonstrated the examples of late clip migration following seemingly successful operations [10-13]. Less than 1% of the postoperative angiograms show an insufficiently secured aneurysm or a rotated clip [14]. Authors demonstrated various techniques in order to avoid clip slippage, although their interests were focused on the particular operative environment. Hundreds of case reports that were never critically appraised. To date, cases of clip slippage have not been pooled and analysed using a validated systematic review methodology. We aimed to collect and summarize the existing literature about clip slippage phenomena using the reproducible and widely accepted PRISMA Statement methodology [15].

Methods and materials

After reaching consensus, the authors developed a detailed protocol [16]. One author searched (November 2017), selected the articles and extracted data. Online Medline, Embase, Web of Knowledge, Cochrane and Google Scholar engines were queried for phrase: 'aneurysm' AND ('clip' OR 'clipping') AND ('slip' OR 'slippage'). Duplicating records were removed using Mendeley Software (ver.1.17.10). Screening was based on titles and abstracts. We accepted original case reports, reviews, commentaries, expert opinions including animal, technical studies, PhD dissertations and patents. No limits in time of publication or language were applied. Google Translate website was used in case of abstracts and articles not in English. Following eligibility assessment, extensive searches for relevant references followed data extraction. Two types of data were deemed valid for further narrative synthesis of evidence: (1) descriptions of postoperative clip slippage and (2) intraoperative manoeuvres intended for prevention of a late slip-off phenomena. Raw data from each patient (Individual Participant Data method, IPD) were analysed as if all slippage occurrences belonged to an assumed single cohort. The evaluation was performed in accordance to Preferred Reporting Items for Systematic Reviews and Meta-Analyses (PRISMA) statement for IPD systematic reviews, which included search, eligibility, extraction, and reporting [17]. Publication bias was not assessed.

We used typical statistical methods for relevant comparisons: chi-square, t-test or Mann-Whitney U

test. Probability value less than 0.05 was considered significant. Statistica v. 13.1 (StatSoft Co, Tulsa, OK; USA) and Prism (GraphPad Software, La Jolla, CA; USA) were used. IRB Committee in the institution of systematic reviews is exempt.

Results

The literature search yielded 3034 records, mostly identified via Google Scholar which explores full-texts for keywords. 'Slip' unrelated to cerebral aneurysm was the main exclusion criterion. Finally, 139 studies were included for the synthesis.

We found 105 original cases reporting late clip migration. In a half of the cases the slipped clip caused bleeding (53.8%; 43/80), half of which were fatal (23/43). A routine postoperative angiography revealed the incidental clip displacement in 32.5% of cases (26/80). Anterior communicating artery (n=15), internal carotid artery (n=21, including 2 blister-like), middle cerebral artery (n=12) and basilar artery (n=7) were commonly encountered locations. In majority of cases (65.3%; 62/95) the authors were not able to provide any reason for clip slippage. Others blamed the defect of clip material in 15 patients (16.0%) and persistent arterial pulsation in 6 (6.4%). Surprisingly, specific features of the particular aneurysm were attributed to only 5 cases of slipped clips (5.3%).

The published reports rarely included aneurysm size, usually only if the aneurysm was giant (85.0%; 8/10). In a quarter of the slippage cases more than one clip was applied (23.3%; 10/43). In 82.9% of cases (68/80) a clip completely slipped off the aneurysm dome. Aneurysm location ($p=0.65$), size ($p=0.26$), rebleeding as the first symptom ($p=0.65$), fatal rebleeding ($p=0.89$) and occurrence in postoperative DSA ($p=0.52$) were not related to the degree (complete or incomplete) of clip migration. On the other hand, complete clip slip-off was significantly more often encountered if a single clip was used (82.1% vs. 44.4%, $p=0.04$). Regarding the direction of slip, in 87.5% of reports the clip migrated off the aneurysm (87.5%; 70/80), whereas in 8 cases (11.4%) the clip was displaced down onto the parent vessel, causing cerebral ischemia in 3 patents (37.5%).

Out of the 139 studies, 78 (56.1%) provided at least one suggestion on how to avoid late clip migration. The most commonly suggested method was placing several clips instead of one (15.8%; 24/139), followed by applying of clip-wrapping technique (7.2%; 10/139) and performing DSA shortly after clipping (4.3%; 6/139). The suggested preventive methods were location-specific, e.g. in case of blood blister-like aneurysm authors postulated placing clips parallel to ICA or clip-wrapping.

PRISMA-IPD Checklist of items to include when reporting a systematic review and meta-analysis of individual participant data (IPD)

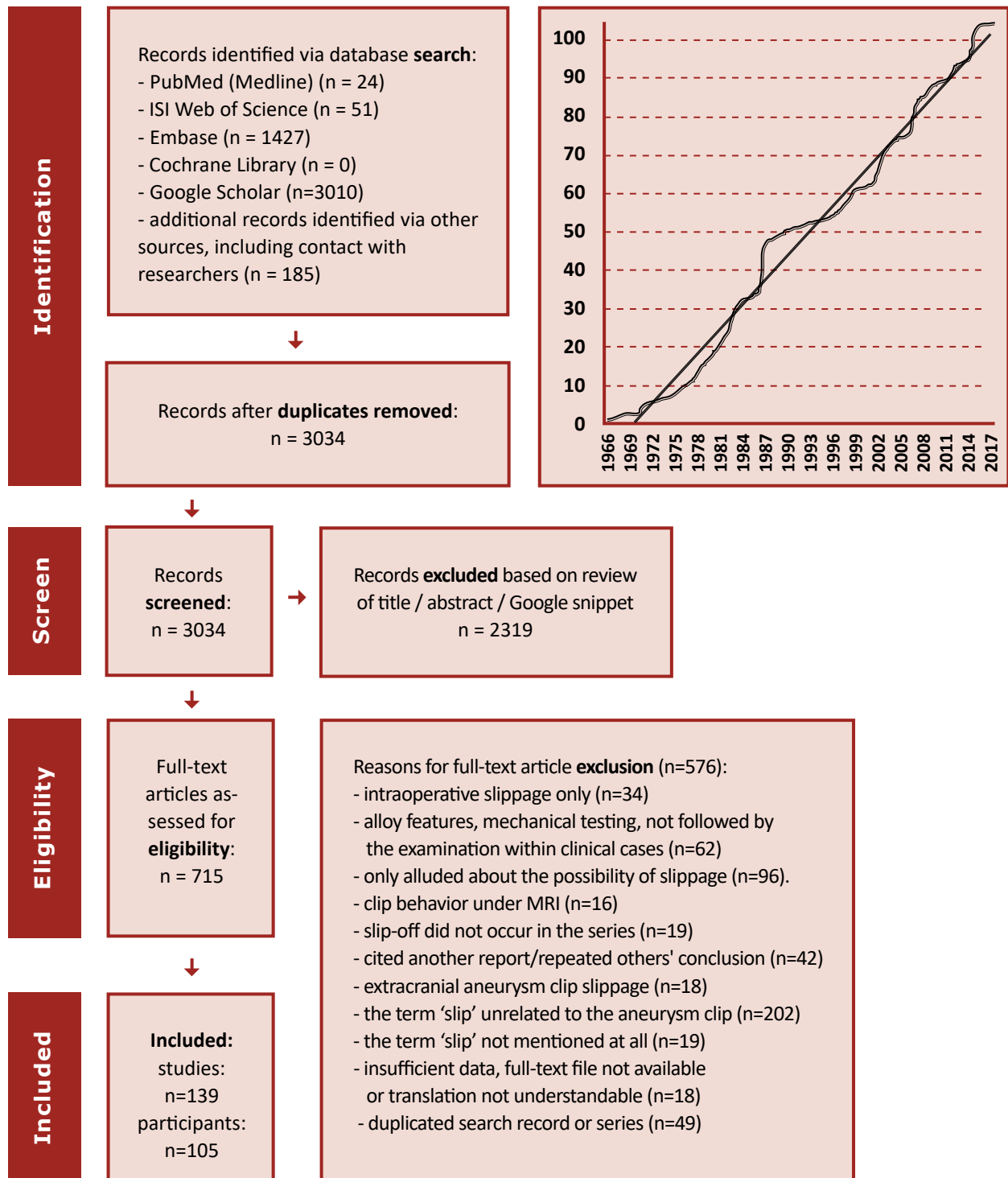
→ go to: <https://ejtcm.gumed.edu.pl/files/54>

Figure 1. Flowchart depicting the strategy for literature search. Cumulative number of cases involving aneurysm clip slippage. The graph demonstrates the constantly increasing publication rate on this subject.

From: Moher D, Liberati A, Tetzlaff J, Altman DG, The PRISMA Group (2009). Preferred Reporting Items for Systematic Reviews and Meta-Analyses: The PRISMA Statement. PLoS Med 6(7): e1000097.

Supplementary Table 1. Full table of studies included in the evidence synthesis.

No	Author	Year	Aneurysm location (size/other features)	Clip/s	Total/partial slip; direction of the slip	Suspected reason of slippage	Avoidance management	Diagnosis
MCA								
1	Matsumoto [1]	1987	MCA	unk	in	clip properties; authors presented a modified non-sliding clip, which blades closed at their tips.		MCA obstruction
2	Matsumoto [1]	1987	MCA	Yasargil	total; out			postop DSA
3	Matsumoto [1]	1987	MCA	unk	partial; out			oculomotor paresis
4	Edner [2]	1978	MCA	straight Heifetz	total; out	clip material fatigue	no filling of the aneurysm was confirmed on DSA.	head radiogram (1.5 y)
5	Nakayama [3]	1987	MCA	misused temporary clip	total; out	unk	none	rebleeding (1.5 mths)
6	Shigemori [4]	1987	MCA	unk	total; out	broad neck	none	unk
7	Hoh [5]	2001	MCA	unk	total; out	unk	none	rebleeding after 3 weeks
8	Asgari [6]	2003	MCA	1 Sugita	partial; out	unk	none	clip slippage not verified
9	Wester [7]	2009	MCA bifurcation	curved	total; out	low closing forces of the long clip	Instead of one long clip, multiple short clips should be used to reconstruct the artery.	fatal rebleeding (after closure of the wound)
10	Wester [7]	2009	MCA fusiform	3 unk	in (across the artery)	unk	none	infarction
11	Takahashi [8]	1987	giant MCA	Sugita	total; out		none	rebleeding (4 d)
12	Asgari [6]	2003	giant MCA	2 Sugita	partial; out	wide calcified neck; only distal 2/3 of clip grasped the neck	none	rebleeding
13	Pia [9]	1980	giant MCA	2 clips	total; out	unk	none	unk

ACoA

14	Kandel [10]	1977	ACoA	unk	total; out	unk	none	unk
15	Czochra [11]	1980	ACoA	unk	total; out	unk	none	postop DSA
16	Sakurai [12]	1987	ACoA	clip and wrapping	total; out	unk	none	rebleeding (3 mths)
17	Haraoka [13]	1987	ACoA	encompassing Heifetz	total; out	incompletely obliterated neck and pulsative forces to the neck over a long period	none	good recovery
18	Asgari [6]	2003	medium-sized ACoA	1 Yasargil Ti (Aesculap)	partial; out	should be differentiated with <i>de novo</i> aneurysm	none	rebleeding
19	Fukui [14]	2004	ACoA	unk	unk; out	unk	none	unk
20	Hayashi [15]	2004	ACoA	straight	total; out	clip head trapped between optic nerves	neurosurgeons	rebleeding (4 d)
21	Chen [16]	2009	ACoA	1 titanium	total; out	unk	none	rebleeding
22	Huh [17]	2012	ACoA	single clip reinforced by a booster clip	total; out	unk	none	rebleeding
23	Kunert [18]	2012	ACoA	unk	total; out	unexplained	none	control CTA
24	Takahashi [8]	1987	ACoA	clipping+-cyanoacrylate glue	total; out	selection of an inappropriate clip, inaccurate clip placement	none	fatal rebleeding (11 d)
25	Takahashi [8]	1987	ACoA	unk	total; out		none	rebleeding (17 d)
26	Yi [19]	2003	ACoA	bayonet standard Yasargil (Aesculap)	total; out	2 mm of neck remnant was supposed	none	postop DSA
27	Xuejian [20]	1998	ACoA	unk	total out	unk	none	fatal rebleeding
28	Yasui [21]	2004	giant ACoA	unk	in	the aneurysm was approached from interhemispheric approach	none	occlusion of parent artery; infarction

29	Izumo [22]	2013	A1	curved Ti	partial; out	unk	none	postop DSA
30	Iida [23]	2017	fusiform A1	straight	total; out	unk	none	rebleeding
ICA								
31	Skultety [24]	1966	ICA	unk	unk	unk	none	fatal
32	Sato [25]	1971	ICA	long, silver	total; out	presumably due to arterial pulsations	none	uneventful clinical course
33	Kariyattil [26]	2013	ICA	bayonet-shaped fenestrated Yasargil	partial; out	Intraop DSA is advised as revealed clip "scissoring effect" causing slippage after apparent right clipping.		
34	Edner [2]	1978	ICA/PCoA	straight Heifetz	total; out	clip head trapped between optic nerves	neurosurgeons	rebleeding (4 d)
35	Sengupta [27]	1978	ICA/PCoA	1 unk	total; out	unk	none	fatal rebleeding
36	Czochra [11]	1980	ICA/PCoA	unk	total; out	unk	none	postop DSA
37	Ebina [28]	1982	ICA/PCoA	Heifetz, then Sugita	total; out	unk	none	rebleeding
38	Horiuchi [29]	2012	ICA/PCoA	Yasargil titanium bayonet	in	scissoring effect	remove immediately scissor-like deformed clip	arterial occlusion (paresis)
39	Drake [30]	1973	board-based ICA/PCoA	1 Sundt	total; out	improper clipping; postoperative hypertension?	intraop and postop DSA; clipping under deep hypotension; clip should be fenestrated or occludes partially the arterial lumen.	clip slipped two times
40	Ikezaki [31]	1987	2 ICA/Oph	tandem of angle fenestrated	partial; in	unk	The blades should be applied parallel to ICA lumen	ICA stenosis
41	Drake [32]	1984	ICA/Oph	1 Sundt	total; out	unk	postop DSA	rebleeding
42	Hatanaka [33,34]	1987	ICA/Oph	unk	total; out	unk	glue applied on the clip spring	rebleeding

43	Melo [35]	2002	giant ICA/ Opth	unk	total; out	weak clip closing pressure	do not resterilize clips; repeat other suggestions to prevent slipping	postop DSA (8 mths)
44	Huh [36]	2011	paradinoid ICA	unk	in	unk	none	ICA occlusion
45	Nemoto [37]	1999	paradinoid ICA	2 clips	total; out	unk	none	postop DSA
46	Heros [38]	1983	giant paraclinoid ICA	unk	total; out	the reinforcing clip blades ruptured the sac while slipping	partial neck clipping with single clip even reinforced by another one should be avoided.	fatal rebleeding
47	Szmuda [39]	2012	giant ICA	2 straight, 1 bayonet Yasargil.	partial; out	weak closing forces of the clip and its resterilisation.	place several clips or stack one on the top of another can prevent clip slippage.	postop DSA
Blood blister-like ICA								
48	Diraz [40]	1993	ICA (BBA)	unk	total; out	due to brain retraction release	Embedding the clip by tearing a small	unk
49	Park [41]	2007	ICA (BBA)	unk	total; out	unk	none	postop DSA (5 wks)
50	Kuroda [42]	2016	ICA (anterior wall)	1 bayonet	total; out	radiation-induced severe	none	postop DSA (5 wks)
BA								
51	Melo [35]	2002	BA	unk	total; out			loss of consciousness
52	Miyachi [43]	1999	BA	unk	total; out	unk	none	postop DSA
53	Peerless [44]	1988	BA	unk	total; out	high arterial pressure	use multiple tandem clips; use clips with short blades to enhance closing pressure.	rebleeding (8 y)

54	Drake [32]	1984	BA	1 Sundt	total; out	unk	postop DSA	fatal rebleeding
55	Carlotti [45]	1996	BA	unk	unk	unk	none	fatal rebleeding
56	Drake [46]	1996	large BA	unk	partial; in	neck shape	none	clip blades stenosed the origins of SCA; ischemia
57	Silverberg [47]	1981	giant BA	unk	unk	unk	apart from slippage, the aneurysm has thrombosed.	postop DSA
VA								
58	Suzuki [48]	1979	VA	unk	total; out	use an adhesive to prevent slippage; in case of slippage risk, optional to clipping is inserting copper wires to facilitate aneurysm thrombosis; postop DSA is essential; clips should cause a trauma to initiate intima healing within its blades.		fatal rebleeding (2 wks)
59	Takahashi [49]	1981	VA	unk	unk	unk	none	fatal rebleeding
60	Fukasawa [50]	1998	dissecting VA	unk	unk	unk	none	unk
61	Haraoka [51]	1999	middle third VA	unk	total; out	unk	none	fatal
PICA								
62	Drake [46]	1984	PICA	older clip	total; out	unk	none	fatal rebleeding
63	Oyesiku [52]	1986	PICA	Heifetz	total; out	The clip migrated to cauda equine (L3-4). "Force of returning brain" has been suggested as a factor of slippage.		low back pain with radiculopathy
64	Porchet [53]	1995	PICA	1 unk	total; out	unk	none	rebleeding
65	Kang [54]	2004	PICA	unk	unk	unk	endovascular embolization	postop DSA 5 days postop
66	Kim [55]	2009	PICA	3 Yasargil (straight, fenestrated, angled)	total; out	The angled clip migrated to sacral (S1) subarachnoid space. The reason of slippage is unknown.		low back pain

Other locations

67	Kanai [56]	1992	hypoglossal artery	straight	partial; in (artery obliteration)	too large aneurysm for clipping or clivus proximity	consider endovascular approach	fatal rebleeding
68	Mann [57]	1984	pericalosal artery	unk	total; out	partial thrombosis of aneurysm	contralateral approach may limit slippage.	postop DSA
69	2005	orbito-frontal	straight Yasargil	partial; out	total; out	initial clipping occurs insufficient if rupture is proximal to parent artery; even 2 mm slippage can cause haemorrhage recur.		rebleeding (5 wks)

Unspecified location

70	Drake [59]	1967	1 unk	unk	total; out	a clip incompletely occluding fundus with coexisting pulsations	coating a residual sac together with a clip and parent vessel.	unk
71	Troupp [60]	1971	1 unk	unk	total; out	unk	none	fatal
72	Gillingham [61]	1979	2 unk (1.1% of series)	Mayfield	unk	unk	none	fatal
73	Guidetti [62]	1970	1 unk	Mayfield	unk	unk	none	fatal rebleeding after 8 hours postop
74	Higuchi, [63,64]	1988 2003	unk	unk	total; unk	unk	none	fatal rebleeding
75	Hillman, Loach [65,66]	1976 1988	unk	unk	total; unk	unk	none	fatal rebleeding
76	Martin, Niikawa [67,68]	1990	unk	unk	total; unk	unk	none	postop DSA
77	Jimbo [69]	1997	1 unk	unk	unk	unk	In severe atherosclerosis the reinforcement with Surgicel® or Biobond® can prevent from slippage.	unk
78	Kano, Troupp, Wermer [60,70,71]	1971 2005 2007	1 unk	unk	unk	unk	unk	unk

79	Park [72]	2014	8 unk (4 atherosclerotic, 4 non-atherosclerotic)	unk	unk	sliding of the clip due to atherosclerotic neck	use multiple clips	unk
80	Nievas [73]	2007	7 cases	unk	total; out	unk	none	postop DSA
81	Shephard [74]	1983	4 cases; unk aneurysms	unk	unk	unk	none	fatal rebleeding
82	Sugita, [75]	1976	unk	Heifetz	unk	unk	broad-necked aneurysms should be secured by clips with more than 80 gm closing pressure.	postop DSA
83	Sundt [76]	1982	unk	Heifetz	unk	unk	none	unk

Proposed management aimed for prevention of further clip slippage

84	Iwama [77,78]	2004	large M1	Dome puncture prevent slipping in or out of aneurysm clip				
85	Yasargil [79]	1974	distal ACA	Coagulation of the neck produces a smaller neck, then less chance of clip slipping.				
86	Ohno [80,81]	1992 1999	ICA, ACA	Sugita straight booster clip was used for preventing a slip-out of the first clip.				
87	Sasaki [82]	1991	ICA	In giant aneurysms additional clips should be applied to prevent first clip slippage.				
88	Inci [83]	2015	ICA	more long clips were placed parallel to the first clip on calcified-necked aneurysm				
89	Hashimoto, Kato [84,85]	1997 2009	ICA	"interlocking" the tandem of angled fenestrated clip blades reinforce their closing pressure and thus reduces the likelihood of slipping.				
90	Ohmoto [86]	1991	cavernous ICA	reinforcing (booster) straight clip was used in wide-necked aneurysm				
91	Uemura [87]	1987	paraclinoid ICA	For prevention of Sugita clip slipping, a small piece of dura is laid between the spring and sphenoid with coating.				
92	Kataoka [88]	1995	paraclinoid ICA	cortex splitting to adjust a clip spring to prevent slippage.				
93	Gianotta [89]	1994	ICA/Opth	Clip slip off the aneurysm is frequent in ICA/Opth; to avoid slippage series of clips should be stacked one on top of another.				
94	Sengupta [90]	1979	ICA bifurcation	aneurysm sac was aspirated shortly after clipping to prevent further slippage				

95	Fujioka, Shigeta [91,92]	1992 2003	ICA (BBA) or dissecting	"clip on wrapping" method to prevent either intra- or postop slippage
96	Kato, Nakagawa, Osawa [93-95]	1986 1991 1993	ICA (BBA)	"Clipping on wrapping" with/without applied on cellulose fabric to prevent slippage.
97	Kazumata [96]	2014	ICA (BBA)	Radial artery to MCA bypass graft is advocated decreases the risk of postop slippage.
98	Yoshimoto [97]	1996	ICA (BBA)	wrapping with muslin gauze may prevent slipping.
99	Otani [98]	2009	ICA (BBA)	right-angled clip blades placed parallel to the parent artery prevent slippage
100	Mooney [99]	2015	ICA (BBA)	placing a thin layer of cotton reinforcement beneath the clip blades
101	Brown [100]	2017	ICA (BBA)	clip blades should be placed along the axis of ICA
102	Drake [46]	1996	BA bifurcation	In order to prevent further clip slipping down and stenosing/kinking the P1 origins, a Drake proposed the tandem clipping, composed of one fenestrated and one straight clip.
103	Hirikoshi [101]	1997	BA bifurcation	If clip blades slip toward BA closing the PCA origins, direct clipping should be abandoned.
104	Fujitsu [102]	1994	VA, BA	"wrap-clipping" technique with Dacron-meshed silastic sheet
105	Sano [103]	1997	dissecting VA	a second curved fenestrated booster clip was placed on blades of the first clip to eliminate its further slippage.
106	Hylton [104]	1988	giant	atheroma removal from aneurysm sac should precede direct clipping
107	Welch [105]	1997	giant	intraaneurysmal thrombus prevents clips from closing and force the clip onto the parent artery; partial thrombectomy while temporary clipping is advised.
108	Wellman [106]	1998	giant	clips placed across the neck require total occlusion, otherwise a pulsating aneurysm neck pose a risk of slipping away or inwards.
109	Kawai [107]	1987	giant	To prevent slipping-in of the clip and artery occlusion, the dome thrombectomy, neck thrombarterectomy, also using CUSA should follow neck clipping.
110	Lawton [108,109]	1994 1999	giant	intraaneurysmal thrombus prevents clips from closing and force the clip onto the parent artery; partial thrombectomy while temporary clipping is advised.
111	Symon [110]	1992	giant	debulking the aneurysm and collapsing its neck diminish the risk of clip slippage toward parent artery.
112	Nakamura [111]	2012	wide-necked	multiple clipping to prevent clip slip-out.
113	Nakano [112]	2000	wide-necked	"Clipping on wrapping" to prevent slip off.
114	Turkmani [113]	2015	aneurysms with a calcified neck	a single clip can slip downward at the calcified neck thus a clip reconstruction should be employed
115	Kato [114]	2012	previously coiled	Specific features of sac and neck of previously coiled aneurysm should be considered preoperatively in order to avoid further slippage.
116	Kiran [115]	2015	very small	double-clip technique (two parallel mini clips) prevents from slipping

117	Giannotta [116]	1995	4 unk	Clip slippage was attributed to older style clips or their improper placement. Recommended preventions: large portion of sac should be dissected first, otherwise clip closing forces would not counteract tethering of fibrous material; multiple and tandem clipping; use of booster clips; evacuating the sac; puncture the sac once neck clipping is complete; do not place clips under hypotensive anaesthesia.
118	Kato [117]	1995	unk	Fenestrated clip itself prevents slippage.
119	Guo [118]	2007		excising a sac may contribute to a clip slippage
120	Hollin [119]	1973		persistence of blood pulsations to the clip
121	Hori, Iwata, Kato, Kodama, Lee, Mizoi, Sugita [120-127]	1976 1979 1982 1987 1988 1997		additional wrapping/coating or adhesive (i.e. cyanoacrylate) use to prevent further slippage.
122	Mayfield [128]	1971		Clip blades should be parallel and incorporate as little of the surrounding tissue as possible.
123	Nievas [129]	2000		Developed several tips to prevent clip slippage: use the mobile fulcrum clip, reduce the amount of sac filling (decrease blood pressure or use a temporary clip), place a second occluding clip parallel to the first one (then correct the first clip), never use a clip that has been left open in the instrument or resterilized for a subsequent operation, leave a depth of at least 2 mm from the tip, resect completely the arachnoid bundles surrounding the aneurysm neck, remove the atheroma before a clip is applied on the ruptured ICA aneurysm, perpendicular clip insertion may lead to blades' cross, the neck resistance should be verified prior to clip placement.
124	Nishi [130]	2007		Wrap-reinforced clipping for slippery aneurysm neck; sequential clip placement to avoid slipping-in and occluding parent vessel (a pilot clip is removed after stabilizing a second clip).
125	Nussbaum [131]	2010		The modified fenestrated clip ("compression clip") was introduced to avoid slipping from atheromatous, thrombotic or previously coiled aneurysms.
126	Origitano [132]	1997		Puncture the sac and perform postop DSA to avoid slippage phenomena.
127	Sano [133]	1991		A double-secured aneurysm closure - fenestrated and straight clips closed across the neck; that combination of clips initiated by Charles Drake.
128	Schmid -Elsaesser [134]	2000		broad-based aneurysms should be secured by more than one clip.
129	Sughrue [135]	2011		incorporating pathological tissues at the neck that can cause clip slippage
130	Sugita [136]	1985		If a clip slips onto the parent artery and causes stenosis, puncturing the sac is indispensable. Placing a second clip prevent slipping, even though the first clip do not open with arterial pulsation. Total wrapping after even successful clipping may prevent postop slipping. Putting some chemical adhesives on clip blades.
131	Sundt [137]	1984		applying a booster clip prevent from slipping
132	Safavi-Abbasi [138]	2016		cotton-clipping and cotton-augmentation strategies
133	Sakata [139]	2015		clip and wrap technique using Gore-Tex sling

Discussion

Our systematic review was divided into two stages: we pooled all valid cases in which an aneurysm clip slid off and collected all studies addressing prevention of clip slippage. By including every type of study into the systematic review, we intended to reveal case reports and authors' own experiences. However, most authors (65.3%) did not provide any reason why the clip slipped off. The incomplete clipping and insufficient amount of used clips were the most commonly stated reasons. On the other hand, tandem clipping seems more durable option proposed by 15.8% of authors in our systematic review [9, 18-20].

The prevention of clip slippage depended on aneurysm location. Specifically, reinforcing with any wrapping material, clip-wrapping methods and placing blades parallel to carotid were proposed in blood blister-like aneurysms [21-25]. Whereas in cases of a clip slipped from ACoA aneurysm, the authors did not provide any suggestions for repair.

Our systematic review pooled reports of slipped cerebral aneurysm clips. Based on this cohort we concluded that by using a single clip the surgeon should consider aneurysm recurrence. It was often speculated in the literature that multiple clipping more seems to be a more durable solution. Plenty of valuable hints on how to avoid postoperative clip slippage were suggested in the literature and we listed all of them based on the specific aneurysm location.

Ethical approval

Formal consent is not required for this type of study.

Informed consent

Informed consent was obtained from all individual participants included in the study.

References

1. Drake CG, Peerless SJ, Hernesniemi JA. Surgery of Vertebrobasilar Aneurysms [Internet]. Vienna: Springer Vienna; 1996. Available from: <http://link.springer.com/10.1007/978-3-7091-9409-6>
2. Giannotta SL. Complication A voidance for Large and Giant Carotid Ophthalmic Aneurysms. In: New Trends in Management of Cerebro-Vascular Malformations [Internet]. Pasqualin A, Da Pian R, editors. Vienna: Springer Vienna; 1994 [cited 2014 Sep 12]. 198-202 p. Available from: <http://link.springer.com/10.1007/978-3-7091-9330-3>
3. Szmuda T, Słoniewski P. Giant Intracranial Aneurysms - Surgical Treatment, Accessory Techniques and Outcome. In: Murai Y, editor. Aneurysm [Internet]. InTech; 2012 [cited 2014 Sep 5]. p. 351–82. Available from: <http://cdn.intechopen.com/pdfs-wm/38617.pdf>
4. Carvi y Nievas M, Höllerhage H. Risk of intraoperative aneurysm clip slippage: a new experience with titanium clips. J Neurosurg [Internet]. 2000 Mar [cited 2014 Sep 5];92(3):478–80. Available from: <http://thejns.org/doi/abs/10.3171/jns.2000.92.3.0478>
5. Carvi y Nievas M. Assessment of the clipping efficacy of intracranial aneurysms: analysis of the employed methodology in relation to case difficulty. Neurol Res [Internet]. 2007 Jul [cited 2014 Sep 3];29(5):506–16. Available from: <http://www.ncbi.nlm.nih.gov/pubmed/17535574>
6. Horiuchi T, Li Y, Seguchi T, Sato A, Aoyama T, Hanaoka Y, et al. Clip blade scissoring with titanium bayonet clip in aneurysm surgery. Two case reports. Neurol Med Chir (Tokyo) [Internet]. 2012 [cited 2017 Nov 26];52(2):84–6. Available from: <http://www.ncbi.nlm.nih.gov/pubmed/22362289>
7. Kariyattil R, Panikar D. Scissoring of a Cobalt Alloy Aneurysm Clip causing Slippage during Cerebral Aneurysm Surgery: Case report and review of literature. Sultan Qaboos Univ Med J [Internet]. 2013 Feb [cited 2014 Sep 2];13(1):179–82. Available from: <http://www.pubmedcentral.nih.gov/articlerender.fcgi?artid=3616789&tool=pmcentrez&render-type=abstract>
8. Asgari S, Wanke I, Schoch B, Stolke D. Recurrent hemorrhage after initially complete occlusion of intracranial aneurysms. Neurosurg Rev [Internet]. 2003 Oct [cited 2014 Sep 2];26(4):269–74. Available from: <http://www.ncbi.nlm.nih.gov/pubmed/12802695>
9. Giannotta SL, Litofsky NS. Reoperative management of intracranial aneurysms. J Neurosurg [Internet]. 1995 Sep [cited 2014 Sep 2];83(3):387–93. Available from: <http://www.ncbi.nlm.nih.gov/pubmed/7666212>
10. McKissock W. Recurrence of an Intracranial Aneurysm after Excision. J Neurosurg [Internet]. 1965 Nov [cited 2017 Nov 26];23(5):547–8. Available from: <http://www.ncbi.nlm.nih.gov/pubmed/5858447>

11. Kim YH, Kim JE, Kang H-S, Han DH. Migration of an aneurysm clip to the sacral subarachnoid space. *Acta Neurochir (Wien)* [Internet]. 2009 Mar 10 [cited 2014 Sep 2];151(6):699–700. Available from: <http://www.scopus.com/inward/record.url?eid=2-s2.0-67650444427&partnerID=tZOtx3y1>
12. Oyesiku NM, Jones RK. Migration of a Heifetz aneurysm clip to the cauda equina causing lumbar radiculopathy. Case report. *J Neurosurg* [Internet]. 1986 Aug [cited 2014 Sep 5];65(2):256–7. Available from: <http://www.ncbi.nlm.nih.gov/pubmed/2941527>
13. Hayashi Y, Kimura M, Satake R, Kinoshita A. Possible participation of clip rotation in the formation of de novo aneurysm. *J Clin Neurosci* [Internet]. 2004 Apr [cited 2014 Sep 6];11(3):331–4. Available from: <http://www.sciencedirect.com/science/article/pii/S0967586803001991>
14. Beltagy M El, Muroi C, Roth P, Fandino J, El Beltagy M, Imhof H-G, et al. Recurrent Intracranial Aneurysms After Successful Neck Clipping. *World Neurosurg* [Internet]. 2010 [cited 2014 Sep 5];74:472–7. Available from: <http://www.sciencedirect.com/science/article/pii/S1878875010002846>
15. Szmuda T, Stoniewski P. Postoperative cerebral aneurysm clip slippage: systematic review. PROSPERO 2014 CRD42014013843 [Internet]. Available from: https://www.crd.york.ac.uk/prospero/display_record.php?RecordID=13843
16. Moher D, Liberati A, Tetzlaff J, Altman DG. Preferred reporting items for systematic reviews and meta-analyses: the PRISMA statement. *PLoS Med* [Internet]. 2009 Jul 21 [cited 2014 Mar 20];6(7):e1000097. Available from: <http://www.pubmedcentral.nih.gov/articlerender.fcgi?artid=2707599&tool=pmcentrez&rendertype=abstract>
17. Stewart LA, Clarke M, Rovers M, Riley RD, Simmonds M, Stewart G, et al. Preferred Reporting Items for Systematic Review and Meta-Analyses of individual participant data: the PRISMA-IPD Statement. *JAMA* [Internet]. 2015 Apr 28 [cited 2016 Dec 27];313(16):1657–65. Available from: <http://jama.jamanetwork.com/article.aspx?doi=10.1001/jama.2015.3656>
18. Wester K. Lessons learned by personal failures in aneurysm surgery: what went wrong, and why? *Acta Neurochir (Wien)* [Internet]. 2009 Sep [cited 2014 Sep 3];151(9):1013–24. Available from: <http://www.scopus.com/inward/record.url?eid=2-s2.0-69249213985&partnerID=tZOtx3y1>
19. Park CK, Shin HS, Choi SK, Lee SH, Koh JS, Martin N. Clinical Analysis and Surgical Considerations of Atherosclerotic Cerebral Aneurysms: Experience of a Single Center. *J Cerebrovasc Endovasc Neurosurg* [Internet]. 2014 Sep 1 [cited 2017 Jul 10];16(3):247. Available from: <https://synapse.koreamed.org/DOIx.php?id=10.7461/jcen.2014.16.3.247>
20. Nakamura K, Kitabayashi M, Murata T. Clipping for Wide-necked Asymptomatic Unruptured Intracranial Aneurysm. *Surg Cereb Stroke* [Internet]. 2012 Mar 19 [cited 2014 Sep 7];40(4):251–6. Available from: https://www.jstage.jst.go.jp/article/scs/40/4/40_251/article
21. Fujioka S. clipping on wrapping method for treatment of short aneurysms. *Surg Cereb Stroke* [Internet]. 2003 [cited 2014 Sep 4];31:375–9. Available from: <http://jlc.jst.go.jp/JST.JSTAGE/scs/31.375?from=Google>
22. Shigeta H, Kyoshima K, Nakagawa F, Kobayashi S. Dorsal internal carotid artery aneurysms with special reference to angiographic presentation and surgical management. *Acta Neurochir (Wien)*. 1992;119(1–4):42–8.
23. Yoshimoto Y, Ochiai C, Nagai M. Cerebral aneurysms unrelated to arterial bifurcations. *Acta Neurochir (Wien)*. 1996;138(8):958–63.
24. Mooney MA, Kalani MYS, Nakaji P, Albuquerque FC, McDougall CG, Spetzler RF, et al. Long-term Patient Outcomes After Microsurgical Treatment of Blister-Like Aneurysms of the Basilar Artery. *Neurosurgery* [Internet]. 2015 Sep [cited 2016 Dec 27];11 Suppl 3:387–93. Available from: <http://content.wkhealth.com/linkback/openurl?sid=WKPTLP:landingpage&an=00006123-201509001-00005>
25. Brown MA, Guandique CF, Parish J, McMillan AC, Lehnert S, Mansour N, et al. Long-term follow-up analysis of microsurgical clip ligation and endovascular coil embolization for dorsal wall blister aneurysms of the internal carotid artery. *J Clin Neurosci* [Internet]. 2017 May [cited 2017 Nov 26];39:72–7. Available from: <http://linkinghub.elsevier.com/retrieve/pii/S0967586816309419>